

# 20 QUESTIONS

---

PHILIP GETSON, D.O.  
CRPS - Face book Live  
September 126, 2020

- “Holmes and Watson are on a camping trip. In the middle of the night Holmes wakes up and gives Dr. Watson a nudge. "Watson" he says, "look up in the sky and tell me what you see."

"I see millions of stars, Holmes," says Watson.

"And what do you conclude from that, Watson?"

Watson thinks for a moment. "Well," he says, "astronomically, it tells me that there are millions of galaxies and potentially billions of planets. Astrologically, I observe that Saturn is in Leo. Horologically, I deduce that the time is approximately a quarter past three. Meteorologically, I suspect that we will have a beautiful day tomorrow. Theologically, I see that God is all-powerful, and we are small and insignificant. Uh, what does it tell you, Holmes?"

**"Watson, you idiot! Someone has stolen our tent!"**



<https://clinicaltrials.gov/ct2/results?recrs=ab&cond=CRPS+I&term=&cntry=US&state=&city=&dist=>

<https://clinicaltrials.gov/ct2/results?recrs=ab&cond=CRPS+I&term=&cntry=US&state=&city=&dist=>



# SPREAD

Spread of the disease is more common than not and can occur up to EIGHT YEARS after the initial diagnosis

Spread occurs horizontally or vertically 95% of the time and diagonally 5%

Schwartzman et al – PAIN – January 2001

# REFERENCES

## Is Fibromyalgia a Generalized Reflex Sympathetic Dystrophy?-

M.Martinez-Lavin- "Clinical & Experimental Rheumatology", 2001: 19:1-3

## Fibromyalgia and the Complex Regional Pain Syndrome: Similarities in Pathophysiology and Treatment

Richard J Wurtman – "Metabolism Clinical and Experimental"-

59-2010 -837-840

# THERMOGRAPHY

A great benefit of infrared imaging is its ability to image the function of the nervous system, especially with chronic pain conditions.

The Nervous System along with the blood vessels creates most of the heat patterns we see using thermal imaging.

A hallmark of CRPS is an excessive vasoconstriction of blood vessels that can cause cold hands and feet.

Thermography provides images of the sympathetic nervous system and given that CRPS is considered by some to be a disease of sympathetic origin, it is the perfect tool for the corroboration of the clinical diagnosis



# Gastrointestinal

Apart from the obvious acid peptic and irritable bowel symptoms, we have to deal with intractable nausea and vomiting. Endoscopically there may be some mild gastric irritation but generally the findings are minimal. Conventional treatment is rarely effective. The etiology is clearly gastroparesis and objectively identified via gastric emptying studies.

We have had great success with the endoscopic administration of Botox into the pyloric sphincter. In many instances one to three such injections have stopped the vomiting for prolonged periods of time.

Another interesting finding is a number of patients with clinical and laboratory confirmed pancreatitis with no other etiology evident save for their CRPS

Other G.I. symptoms include:

Dysphagia, indigestion

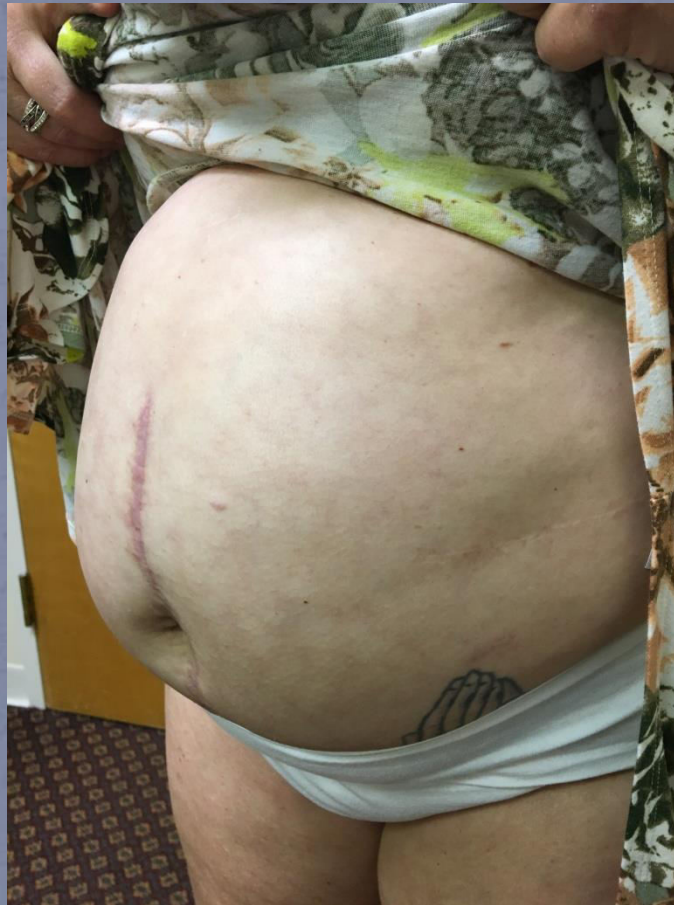I.B.S

Constipation ( frequently opioid induced)

Biliary dyskinesia



# GASTROPARESIS ?



# Urinary

Commonly, patients experience urinary incontinence, dysuria or inability/difficulty voiding. The condition is usually misdiagnosed as Interstitial Cystitis. The problem has responded marginally to conventional medications. Bladder pacemakers have been somewhat useful. Again, Botox injections into the pelvic floor have helped a great number of sufferers. Additionally, I have found that lumbar epidural infusions of bupivacaine over a 5 day period works very well. Ketamine has resolved this to a small degree as well.

# VERTIGO

Vertigo is common as an early symptom  
Sometimes it is positional but mainly it is  
movement related

Treatment is based upon reducing the  
CRPS symptoms and occasionally  
meclizine helps make the vertigo  
tolerable pending the improvement of the  
disease process



# SYNCOPE

“ Syncope is common in patients with CRPS especially with lower limb involvement. Autonomic dysregulation of the lower extremities leads to sympathetic vasoconstriction and venous pooling which can predispose these patients to syncope.”

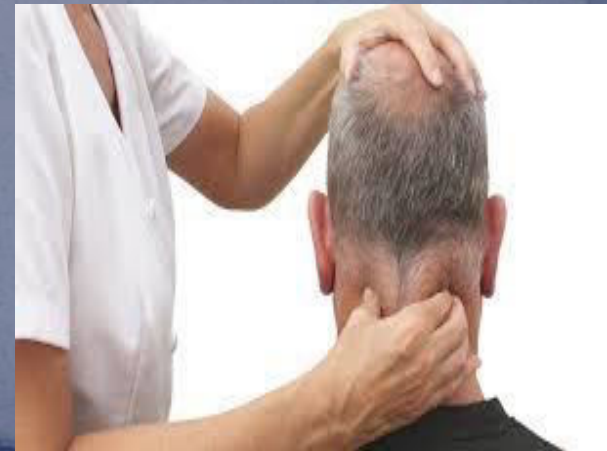Syncope in Complex Regional Pain Syndrome – Smith et al. – *Clinical Cardiology* 34.4; 222-225 (2011)

# HEADACHES

MIGRAINES(?)

TENSION HEADACHES

GREATER OCCIPITAL NEURALGIA



# VISUAL DISTURBANCE

DOUBLE VISION  
BLURRED VISION  
OCCULAR MIGRAINES  
VISION LOSS  
PHOTOPHOBIA  
BURNING OF THE EYES



# OTORHINOLARYNGOLOGIC

Patients report significant otophobia.

Recently there has been an increase in individuals reporting significant discomfort from vibration, specifically the bass of stereos even through walls and from adjacent motor vehicles while travelling.

Intermittent and transient hoarseness comes from the effect of the disease on the branchial plexus and is frequently misdiagnosed as immune compromise

# DENTAL

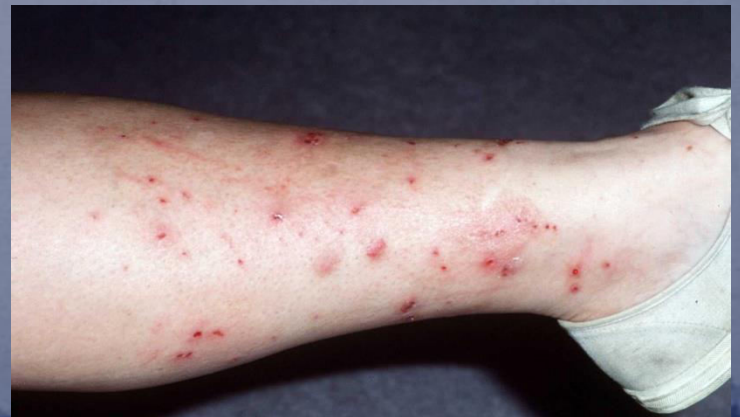Unfortunately dental disease is rampant in patients with CRPS

Part of this stems from dietary indiscretions, part from immune system compromise and part from the disruption of the dental nerve roots.

Perhaps the greatest reason is that the side effects of common medications prescribed for chronic pain lead to a change in lifestyle, poor oral hygiene, poor nutrition and a loss of saliva (dry mouth) that result in decay, periodontal disease and ultimately tooth loss

# DERMATOLOGIC

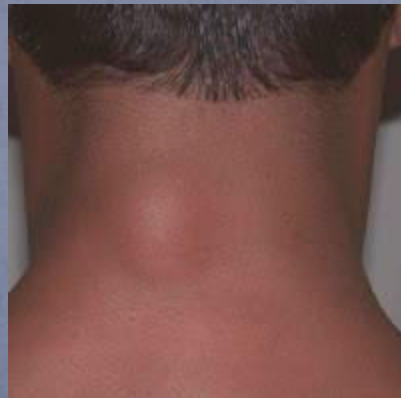- The most common finding apart from dry skin or hyperhidrosis is neurodermatitis. This can occur randomly on any area of the body. Lesions have the appearance of small acne-type eruptions that itch for hours to days and disappear spontaneously. There is no specific etiology apart from the CRPS and no treatment save for topical low potency steroids or anti-histamines to reduce the itch. If scratched they will scar





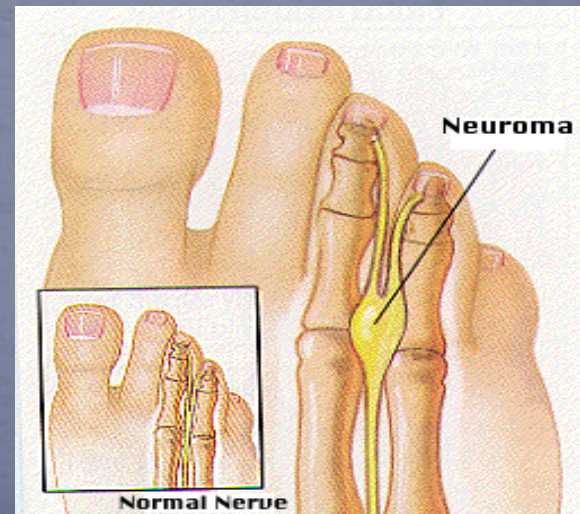
# DERCUM'S DISEASE

**Dercum's disease**, is a rare condition characterized by multiple, painful lipomas. These lipomas mainly occur on the trunk, the upper arms and upper legs. The understanding of the cause and mechanism of Dercum's disease remains unknown. Possible etiologies include: nervous system dysfunction, mechanical pressure on nerves, adipose tissue dysfunction and trauma.



# PODIATRIC

Morton's neuroma is a mechanically induced degenerative neuropathy predominantly affecting the second and third common digital nerves. It is not actually a tumor but a thickening of the tissue that surrounds the nerves leading to the toes. It is eight to ten times more likely to occur in women than in men and most prevalent in middle aged women



# COGNITIVE DYSFUNCTION

There have been an increasing number of CRPS patients with cognitive issues. Mostly these are STML, word retrieval & difficulty with expression. It has been theorized that this is medication related but it occurs in individuals who take virtually no meds. Current thoughts abound with no single answer surfacing as being definitive.



# OTHER SYMPTOMS

- Shortness of breath
- Inability to take a deep breath
- Neurogenic edema
- Muscle weakness/atrophy
- Endocrine dysfunction – adrenal, thyroid, hormonal imbalance
- Gardner Diamond Syndrome – spontaneous bruising in uninjured areas
- Lethargy
- Fatigue
- Sleep Disturbance

“Systemic Complications of Complex Regional Pain Syndrome”-  
Robert J. Schwartzman -*Neuroscience & Medicine*, 2012,3,225-242

# SPREAD

Spread of the disease is more common than not and can occur up to EIGHT YEARS after the initial diagnosis

Spread occurs horizontally or vertically 95% of the time and diagonally 5%

Schwartzman et al – PAIN – January 2001

WHEN  
YOU HAVE  
ELIMINATED THE  
IMPOSSIBLE

WHATEVER REMAINS

HOWEVER IMPROBABLE

MUST BE THE



TRUTH

SHERLOCK HOLMES



# PHILIP GETSON, D.O.

[WWW.DRGETSON.COM](http://WWW.DRGETSON.COM)

